

Initial Proof-of-Concept Study on Immediate Effects of External Advanced Pneumatic Compression on Pharyngeal and Laryngeal Internal Lymphedema Using a Fluoroscopic Measurement Tool

Journal: *Head & Neck: Journal of the Sciences and Specialties of the Head and Neck*
Publication Date: epub November 2024
Authors: Jessica W. Gregor, Brent Chang, Nandita Keole, Alyssa McGary, Samir Patel

OBJECTIVE

To (1) report the immediate impact of a single advance pneumatic compression device (APCD) treatment on internal head and neck cancer-related lymphedema (HNCRL) and (2) describe fluoroscopy and specialized software as a clinically useful and accessible tool for assessing HNCRL.

BACKGROUND

External and internal HNCRL is a common and chronic consequence of head and neck cancer and its treatments, both surgical and nonsurgical. Post-treatment incidence rates of HNCRL are approximately 90%, yet it is underrecognized and underdiagnosed.¹⁻⁵ Untreated HNCRL results in fibrosis which is a precipitating and exacerbating factor for worsened swallow function. Symptoms vary depending on the location and extent of lymphatic disruption.⁶

Currently, internal HNCRL can be clinically assessed endoscopically using a visuoperceptual, ordinal rating scale. While no formal HNCRL rating tool or scale has been published involving fluoroscopy, the lateral fluoroscopic scout obtained during a videofluoroscopic swallow study (VFSS) has been used to identify and measure the development of internal HNCRL. APCDs have shown external HNCRL reduction after a single treatment, whereas internal HNCRL reduction has not yet been assessed.^{7,8}

METHODS

A retrospective study of 30 HNC survivors at least three months post-radiation therapy underwent a single 32-minute treatment of APCD (Flexitouch® Plus, Tactile Medical®). Outcome measures included internal structural width measured using fluoroscopic scouts and TIMS Review software (TIMS Medical), external measures using a tape measure, and a post-treatment survey.

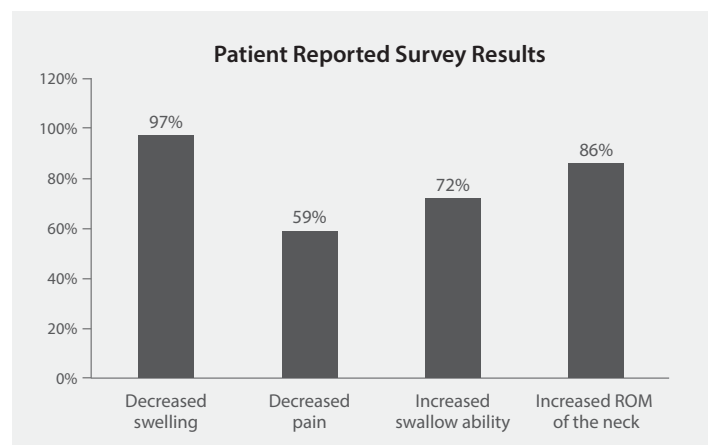
RESULTS

All 30 subjects had immediate reductions both externally and internally after a single treatment, and there was a statistically significant decrease in all the external and internal measurements.

Pre/Post Percentage Changes	
	Mean Reduction
Velar width	8.4%
Epiglottic width	9.7%
Posterior pharyngeal wall width	9.9%
C2	10.6%
C3	9.0%
C4	10.0%

External Measures*	
	Mean Reduction
Neck circumference	2.7%
Tragus to tragus	3.1%
Left tragus to nose	3.7%
Right tragus to nose	2.6%
Left tragus to eye	3.8%
Right tragus to eye	2.4%
Left tragus to mouth	3.1%
Right tragus to mouth	2.6%

*None of the 30 patients had an increase in any of the external measures post treatment.



DISCUSSION

This study shows that software and fluoroscopy can detect changes and mobilization in lymph fluid from interventions like APCD. The software identified immediate reductions in both internal and external tissue thickness after a single treatment, even in late-stage patients, challenging the notion that fibrosis is irreversible. TIMS Review software and fluoroscopy were highlighted as commercially available tools for assessing anatomical and functional changes. These results highlight the need for comprehensive care pathways, patient access to resources like APCD, and interdisciplinary collaboration to support long-term management.

Further prospective and adequately powered studies are needed to examine the functional impact on swallowing safety and efficiency, inform treatment guidelines for HNCRL (e.g., clarify the optimal time frame, duration, and frequency of APCD), and evaluate the efficacy of APCD versus MLD.

KEY POINTS

- A single 32-minute treatment with an external APCD immediately impacts the extent of edema in the pharynx and larynx in post-radiated HNC survivors.
- Reduction of pharyngeal and laryngeal edema is of particular importance in the prevention and rehabilitation of swallow function in HNC patients.
- Endoscopic and fluoroscopic modalities should be utilized, as they are complementary and provide the most robust assessment of internal HNCRL.

CONCLUSION

HNCRL is widespread. A 32-minute APCD treatment significantly reduced edema in the pharynx and larynx, with average reductions in the velar width (8.4%), epiglottis (9.7%), and posterior pharyngeal wall (9.9%), as well as the external thickness of the face and neck.

About the authors:

¹Department of Otolaryngology – Head and Neck Surgery, Mayo Clinic, Phoenix, Arizona.

²Department of Quantitative Health Sciences, Mayo Clinic, Phoenix, Arizona.

³Department of Physical Medicine and Rehabilitation, Mayo Clinic, Phoenix, Arizona.

⁴Department of Radiation Oncology, Mayo Clinic, Phoenix, Arizona.

References:

1. Parke SC, Langelier DM, Cheng JT, Kline-Quiroz C, Stubblefield MD. State of Rehabilitation Research in the Head and Neck Cancer Population: Functional Impact vs. Impairment-Focused Outcomes. *Curr Oncol Rep.* 2022;24(4):517-532. doi:10.1007/s11912-022-01227-x
2. Deng J, Murphy BA, Dietrich MS, et al. Impact of secondary lymphedema after head and neck cancer treatment on symptoms, functional status, and quality of life. *Head Neck.* 2013;35(7):1026-1035. doi:10.1002/hed.23084
3. Jeans C, Brown B, Ward EC, et al. Comparing the prevalence, location, and severity of head and neck lymphedema after postoperative radiotherapy for oral cavity cancers and definitive chemoradiotherapy for oropharyngeal, laryngeal, and hypopharyngeal cancers. *Head Neck.* 2020;42(11):3364-3374. doi:10.1002/hed.26394
4. Jeans C, Ward EC, Brown B, et al. Association between external and internal lymphedema and chronic dysphagia following head and neck cancer treatment. *Head Neck.* 2021;43(1):255-267. doi:10.1002/hed.26484
5. Jackson LK, Ridner SH, Deng J, et al. Internal Lymphedema Correlates with Subjective and Objective Measures of Dysphagia in Head and Neck Cancer Patients. *J Palliat Med.* 2016;19(9):949-956. doi:10.1089/jpm.2016.0018
6. Doersam JK, Dietrich MS, Adair MA, Rhoten B, Deng J, Ridner SH. A Comparison of Symptoms Among Patients with Head and Neck or Truncal Lymphedema and Normal Controls. *Lymphat Res Biol.* 2019;17(6):661-670. doi:10.1089/lrb.2019.0034
7. Mayrovitz HN, Ryan S, Hartman JM. Usability of advanced pneumatic compression to treat cancer-related head and neck lymphedema: A feasibility study. *Head Neck.* 2018;40(1):137-143. doi:10.1002/hed.24995
8. Gutierrez C, Karni RJ, Naqvi S, et al. Head and Neck Lymphedema: Treatment Response to Single and Multiple Sessions of Advanced Pneumatic Compression Therapy. *Otolaryngol Head Neck Surg.* 2019;160(4):622-626. doi:10.1177/0194599818823180

Tactile Medical

3701 Wayzata Blvd, Suite 300
Minneapolis, MN 55416 USA

tactilemedical.com

Customer Care

Text or Call: 612.355.5100
Toll Free Phone: 833.3TACTILE (833.382.2845)
Fax: 612.355.5101 / Toll Free Fax: 866.435.3949
Email: customerservice@tactilemedical.com
Hours: 7 a.m. to 5:30 p.m. CT, Monday–Friday

Tactile
MEDICAL®
HEALING RIGHT AT HOME