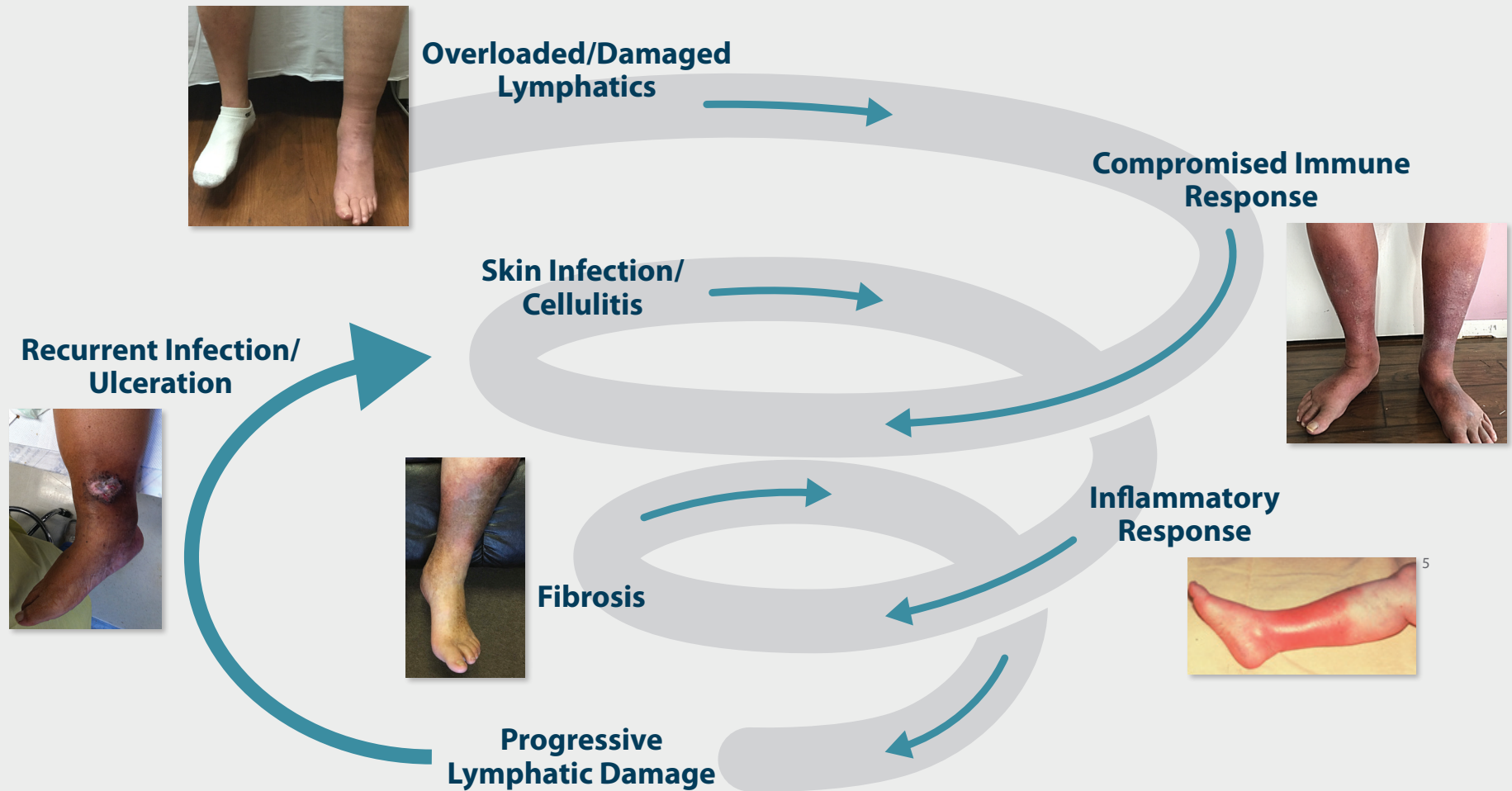


# THE PROGRESSIVE SPIRAL OF LYMPHATIC DYSFUNCTION<sup>1,2,3,4</sup>



1. Ruocco E, et al. Phlebolympheidema: disregarded cause of immunocompromised district. *Clin Dermatol*. 2012 Sep-Oct;30(5):541-3. doi: 10.1016/j.clindermatol.2012.04.004.

2. Dean SM. Cutaneous Manifestations of Chronic Vascular Disease. *Prog Cardiovasc Dis* (2018) <https://doi.org/10.1016/j.pcad.2018.03.004>

3. Sclelsi R, et al. Morphological changes of dermal blood and lymphatic vessels in chronic venous insufficiency of the leg. *Int Angiol*. 1994 Dec;13(4):308-11

4. Farrow W. Phlebolympheidema—A Common Underdiagnosed and Undertreated Problem in the Wound Care Clinic. *The Journal of the American College of Certified Wound Specialists*. 2010;2(1):14-23.

5. Permission for use of image courtesy of Dr. Bruce Ruben

Permission for use of patient images on file at Tactile Medical.